

Single-incision Anterior Approach for Total Hip Arthroplasty on an Orthopaedic Table

Joel M. Matta, MD; Cambize Shahrदार, MD; and Tania Ferguson, MD

Dislocation remains the leading early complication of total hip arthroplasty; surgical approach and implant positioning have been recognized as factors influencing total hip arthroplasty stability. We describe a total hip arthroplasty technique done through a single, tissue sparing anterior approach that allows implantation of the femoral and acetabular components without detaching or sectioning any of the muscles and tendons around the hip joint. A series of 437 consecutive, unselected patients who had 494 primary total hip arthroplasty surgeries done through an anterior approach on an orthopaedic table from September 1996 to September 2004 was reviewed. There were 54 hybrid and 442 uncemented hips in the 437 patients (57 bilateral). The average patient age was 64 years. Radiographic analysis showed an average abduction angle of 42°, with 96% in the range of 35° to 50° abduction. The average cup anteversion was 19° with 93% within the target range of 10° to 25°. Postoperative leg length discrepancy averaged 3 ± 2 mm (range, 0–26 mm). Three patients sustained dislocations for an overall dislocation rate of 0.61%, and no patients required revision surgery for recurrent dislocation. There were 17 operative complications, including one deep infection, three wound infections, one transient femoral nerve palsy, three greater trochanter fracture, two femoral shaft fractures four calcar fractures, and three ankle fractures. Operative time averaged 75 minutes (range 40–150 minutes), and the average blood loss was 350 mL (range, 100–1300 mL). The mean hospital stay was 3 days (range, 1–17 days). The anterior approach on the orthopaedic table is a minimally invasive technique applicable to all primary hip patients. This technique allows accurate and reproducible com-

ponent positioning and leg-length restoration and does not increase the rate of hip dislocation.

Level of Evidence: Therapeutic study, Level IV-1 (case series). See the Guidelines for Authors for a complete description of levels of evidence.

Although total hip arthroplasty (THA) remains one of the most successful surgeries done by orthopaedic surgeons, complications including dislocation, leg-length discrepancy, and abductor dysfunction/gait disturbance remain problems.^{1,4,7–12,14,18,20–24} Dislocation remains the leading early complication of THA, occurring in 0.4% to 11% of patients; 22% to 44% of patients with dislocation require revision surgery for instability.^{7–10,12,20,21,23,24} Surgical approaches and implant positioning have been recognized as factors influencing hip arthroplasty stability. The standard posterolateral approach requires division of the posterior hip capsule and the external rotators, and is associated with high dislocation rates.^{8,12,20,21,24} The anterolateral approach is more resistant to dislocation, but detaching the gluteus medius and minimus insertions from the greater trochanter is associated with abductor dysfunction and postoperative limp (reported in as many as 20% of patients).^{1,14,27} The relationship between component malposition and an increased dislocation rate has been evaluated by many authors.^{18,21,24} Efforts to reduce complications associated with surgical exposure of the hip has lead some surgeons to question the traditional operative techniques.^{3,17,19,25,26,29}

The Hueter anterior approach to the hip has been used by Judet and Judet for hip joint exposure for arthroplasty techniques since 1947.^{15,16} The initial technique involved removal of the anterior tensor fascia lata from the anterolateral iliac crest, sectioning the reflected head of the rectus, and release of the piriformis. Since the initial description, the approach has been modified to allow exposure of the acetabulum and femur through a single, anterior incision that does not require release of any muscles or tendons from the pelvis or femur. The posterior capsule and

From the Department of Orthopaedic Surgery, Good Samaritan Hospital, University of Southern California, Los Angeles, CA.

Dr. Joel M. Matta certifies that he receives royalties from OSI and is a consultant for J&J DePuy. Drs. Ferguson and Shahrदार certify that they have no commercial associations.

Each author certifies that the institution has waived approval for the human protocol for this investigation and that all investigations were conducted in conformity with ethical principles of research.

Correspondence to: Joel M. Matta, MD, John C. Wilson Chair of Orthopaedics, Good Samaritan Hospital, 637 South Lucas Avenue, Suite 605, Los Angeles, CA, 90017. Phone: 213-977-2990; Fax: 213-977-4199; E-mail: info@hipandpelvis.com.

DOI: 10.1097/01.blo.0000194309.70518.cb

external rotators are left intact, potentially decreasing the instability and dislocations associated with the release of these structures required for the traditional posterior approach. Furthermore, the minimus and medius insertions remain intact in an effort to reduce the postoperative limp and abductor dysfunction reported with the lateral and anterolateral approaches.¹⁹

This technique was first used by the senior author (JMM) in 1996, and is now used for all primary THAs unless there is a posterior acetabular defect that requires bone graft and plate fixation. The exposure allows implantation of cemented and uncemented femoral and acetabular components and has been used with standard available implants with well-established designs.^{16,17,20,26} With the patient positioned supine on the orthopaedic table [Judet (Tasserit, Sens, France) or PROfx table (Orthopedic Systems Inc., Union City, CA)], image intensification is used to ensure the accuracy of acetabular component positioning, leg length, and offset. The surgery has evolved during the last 8 years, and is now typically done through an incision ≤ 10 cm long.

We hypothesize that this anterior tissue sparing exposure allows consistent, accurate component positioning and leg length restoration, and that the technique does not increase the overall complication rate associated with primary THA. We describe the surgical technique of this single incision anterior approach to the hip, and evaluate the radiographic data to assess component position and leg length. We evaluated the dislocation rate and the surgical data to identify the rate of early complication with this technique.

MATERIALS AND METHODS

The single-incision anterior approach was used by the senior author for the first time in 1996, and subsequently was used for all patients presenting for THA who did not have a contraindication to the technique (a posterior defect of the acetabulum requiring bone grafting). The senior author's patient database was used to identify a consecutive series of unselected patients who had primary THA through a single anterior incision between September 13, 1996 and September 7, 2004. Patients who had previous hip surgery before this THA were excluded from the study, as were patients having primary arthroplasty for femoral or acetabular fracture. Patients with fewer than 3 months of followup were excluded. We identified 437 patients having primary THA to treat primary arthritis attributed to osteonecrosis, osteoarthritis, posttraumatic arthritis, developmental dysplasia, or rheumatoid arthritis during this time. Three hundred sixty-four patients had unilateral hip arthroplasty, eight patients had staged bilateral arthroplasties (the second hip done 3 months or more after the first), and 57 patients had simultaneous bilateral surgery for a total of 494 hip arthroplasties. Fifty-four stems were cemented and 442 stems were cementless. The mean patient age was 64 years (range, 27–91 years).

The patients were placed in supine position on an orthopaedic table. From September 1996 to February 2003, the Judet/Tasserit orthopaedic table was used exclusively but went out of production in 1996. In February 2003, the PROfx table (Orthopedic Systems, Inc., Union City, CA) became available and preferentially was used. The leg was not draped free but was attached to a mobile spar that can apply traction, rotate, and angulation to the leg in all directions (Fig 1). The contralateral hip was placed in neutral rotation, extension, and abduction-adduction to serve as a radiographic control for the operated side. The operative leg was set in slight internal rotation to enhance the landmark of the natural bulge of the tensor fascia lata muscle. Pneumatic compression boots were applied to both legs for intraoperative deep venous thrombosis (DVT) prophylaxis. Preoperative templating of radiographs gave an initial plan for acetabular shell size, level of neck cut, femoral stem size, and head-neck length.

Before 2002, the surgical procedure was done through the classic Smith-Petersen approach. In 2002, the senior author's arthroplasty surgical volume increased substantially. At this same time, an emphasis was made to minimize unnecessary soft tissue dissection and use a shorter incision length. This tissue-sparing incision started 2 cm posterior and 1 cm distal to the anterior superior iliac spine (ASIS). This straight incision extended in a distal and slightly posterior direction to a point 2 to 3 cm anterior to the greater trochanter (Fig 2), for a total of 8 to 10 cm. The fascia lata was incised over the tensor in line with the skin incision. Blunt dissection around the medial aspect of the tensor within the sheath of the incised aponeurosis developed the interval between the tensor and sartorius superficially. Continued blunt dissection along the medial tensor in the posterior and proximal directions allowed palpation of the lateral hip capsule. A cobra retractor was placed along the superolateral hip capsule. A Hibbs retractor was used to retract the sartorius and rectus femoris medially, exposing the reflected head of the rectus that follows the lateral acetabular rim. A small periosteal elevator was placed just distal to the reflected head and was directed medial and distal to elevate the iliopsoas and rectus femoris



Fig 1. A photograph shows the patient positioning on a PROfx (OSI) table. The patient is positioned supine on the PROfx table with both legs attached to mobile spars. The spars allow the patient's legs to be positioned freely in any direction. The position of femoral preparation is shown, with the hip hyper-extended and externally rotated. Also shown is the femoral hook attachment, which aids delivery of the proximal femur anteriorly and lateral during the broaching process.

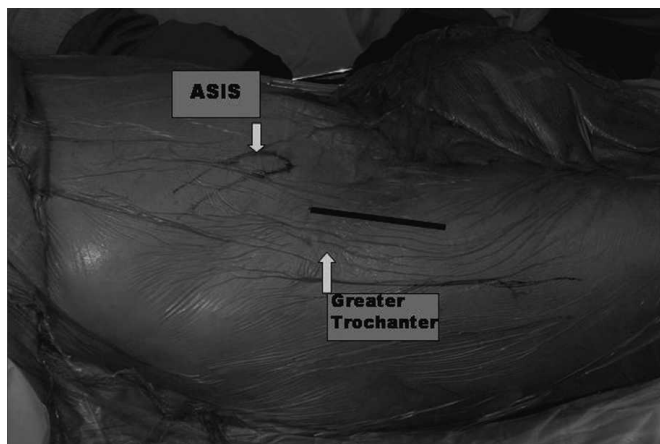


Fig 2. A photograph shows the anterior approach to the hip. The incision is started slightly lateral and distal to the anterior superior iliac spine and proceeds over the bulge of the tensor fascia lata, ending slightly anterior to the palpable greater trochanter.

muscles from the anterior capsule. The elevator opened a path for a second cobra retractor, which then was placed on the medial hip capsule (Fig 3).

The lateral femoral circumflex vessels were observed as they cross the distal portion of the wound. These vessels were clamped, cauterized, and transected. Additional distal splitting of the aponeurosis that overlies the anterior capsule, and at times excision of a fat pad, enhanced exposure of the capsule and the origin of the vastus lateralis muscle. The capsulotomy was done in an L-shaped fashion, and the proximal portion of the lateral

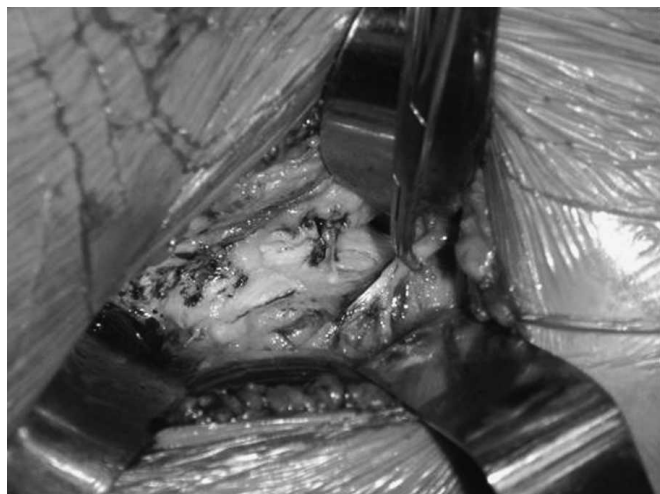


Fig 3. A photograph shows the anterior exposure of the hip capsule. A cobra retractor is placed between the tensor and the lateral hip capsule. A second is placed on the medial hip capsule, reflecting the rectus femoris anteromedially. The lateral circumflex vessels are seen in the distal wound and can be cauterized.

capsule detached from the sulcus between the anterolateral neck and greater trochanter. The distal anterior capsule was detached from the femur at the anterior intertrochanteric line. The anterior and lateral flaps then were tagged for subsequent repair and the cobra retractors were replaced inside the capsule, exposing the femoral neck.

We have found that preliminary hip dislocation before the neck osteotomy allows exposure of the posterior and medial neck and improves mobilization of the femur for subsequent preparation. Infrequently, dislocation is made difficult because of protrusio or previous acetabular fracture, and in these unusual cases the neck is cut in situ. In order to dislocate the hip, a narrow Hohmann retractor was placed on the anterolateral acetabular rim and the anterolateral labrum was excised, exposing the articulation. Distal traction on the extremity creates a small gap between the femoral head and the roof of the acetabulum. A femoral head skid (Aesculap, Central Valley, PA) was placed into the gap, and then placed in a more medial position to release the ligamentum teres and completely free the femoral head of all attachments. The traction was partially released, and external rotation of the limb allowed the hip to be dislocated anteriorly. External rotation of the femur was accomplished by rotation of the leg spar rotation wheel. If the patient is very osteoporotic, undue force from the rotation wheel can fracture the tibia or ankle. For this reason, two modifications were created to aid in the dislocation procedure. The scrubbed surgical assistant can aid dislocation by grasping the femoral condyles and applying additional rotation, therefore downloading the torque applied to the distal extremity. Preferentially, a femoral head corkscrew can be placed into the head before dislocation and used to externally rotate and lateralize the femoral head. After dislocation, the hip was externally rotated 90°, and a narrow Hohmann retractor was placed distal to the lesser trochanter and beneath the vastus lateralis origin. The capsule on the medial neck was then transected parallel to the neck, exposing the lesser trochanter and the medial posterior neck.

The hip was reduced by internal rotation, and the neck cut done. With the cobras placed around the medial and lateral neck, a reciprocating saw was used to cut the neck at the templated level (Fig 4). The neck cut was completed with an osteotome that divides the lateral neck from the medial greater trochanter, and was directed posterior and slightly medial to avoid fracture of the greater trochanter. The femoral head corkscrew was used to remove the head with care taken to protect the tensor from laceration by the sharp edge of the neck as it was extracted.

The acetabulum was observed and prepared. External rotation of the femur of about 45° facilitates acetabular exposure. Light traction also limits femoral interference. Too much traction will tighten the iliopsoas and pull the femur into an anterior obstructing position. A bent Hohmann retractor was placed over the anterior rim of the acetabulum to retract the anterior muscle, with care taken to avoid perforation of the anterior musculature and soft tissues. A cobra retractor was placed posteriorly with the tip on the mid-posterior rim (Fig 5A). The labrum was excised, and the prominent band of inferior capsule incised longitudinally to facilitate placement of the acetabular liner. Reaming was then done (Fig 5B). The acetabular component was inserted under

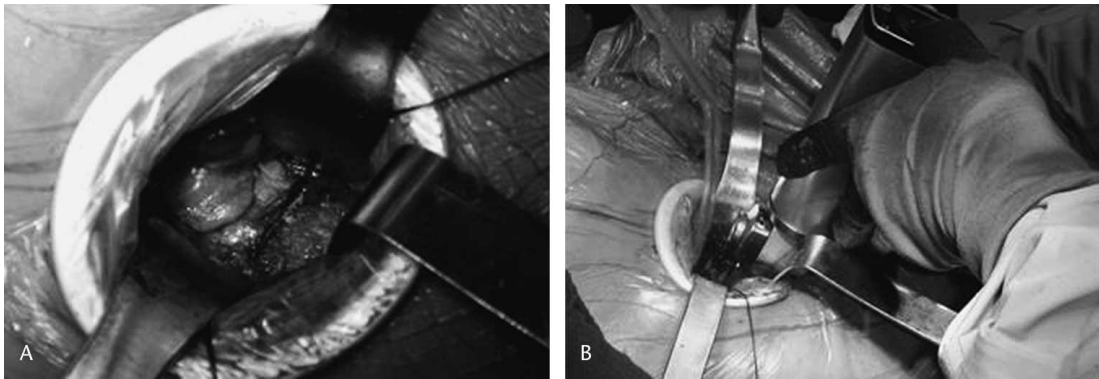


Fig 4A–B. (A) A photograph shows the femoral neck being cut with the head in the reduced position. The lesser trochanter can be palpated and the intertrochanteric line can be observed easily. (B) An oscillating saw is used to cut the neck at the level defined by the preoperative template.

fluoroscopic guidance in all patients, and the leg lengths were compared intraoperatively using imaging after hip reduction with the trial components. The acetabular prosthesis was inserted with a curved handle inserter that reduces pressure on the distal wound. The tendency with this technique is to place the cup in an anteverted, vertical position because of the soft tissue interference with the cup inserter. To ensure accuracy of component position, image intensification can be used to verify the abduction angle and anteversion as the prosthesis is sequentially seated (Fig 6). Once the prosthesis was inserted, the liner was inserted and any acetabular osteophytes were removed.

Femoral exposure was aided by a femoral hook. The hook attached to a hook bracket attached to the table. It was designed to facilitate exposure of the femur through the small anterior incision (Fig 7A). After acetabular insertion, the gross traction control on the leg spar was released and the femur internally rotated to neutral. The femoral hook was placed just distal to vastus ridge and around the posterior femur. The femur was externally rotated 90° and the hip hyperextended and adducted.

The hook was then attached to the most convenient hole on the bracket, which was attached to a jack on the table. Elevation of the jack causes the hook to deliver the proximal femur anteriorly, aiding femoral preparation. The surgeon should monitor the tension on the leg during elevation of the hook, as too much tension may cause fracture of the trochanter. A cobra was placed with its tip on the posterior femoral neck, and a trochanteric retractor was placed over the tip of the trochanter. The lateral capsular flap was detached from the base of the neck in an anterior to posterior direction, facilitating observation of the medial greater trochanter and enhancing femoral mobility (Fig 7B). Any lateral neck remnant was excised with a rongeur.

Although any stem can be used with this approach, stems requiring strait reamers for canal preparation are more difficult because they require the most anterior mobilization of the femur to allow access down the canal. We prefer systems that offer an offset broach handle, which more easily is introduced into the proximal femur without further release of the soft tissues. If further mobilization of the femur is necessary, it can be accom-

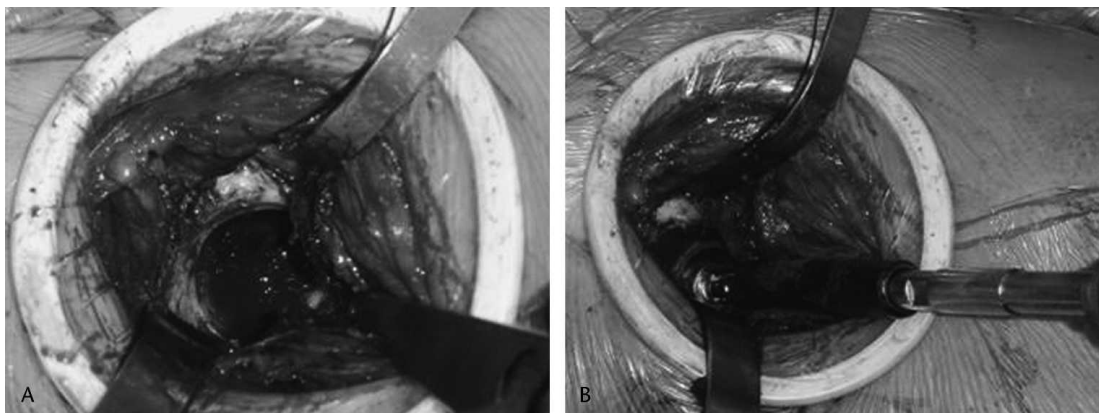


Fig 5A–B. Photographs show acetabular exposure and reaming. The acetabulum is observed easily with the anterior approach. A bent Hohmann/anterior acetabular retractor is placed over the anterior rim, and a cobra retractor is placed at the posterior acetabulum. The reamer is introduced easily through the anterior approach and can be observed during the reaming process.

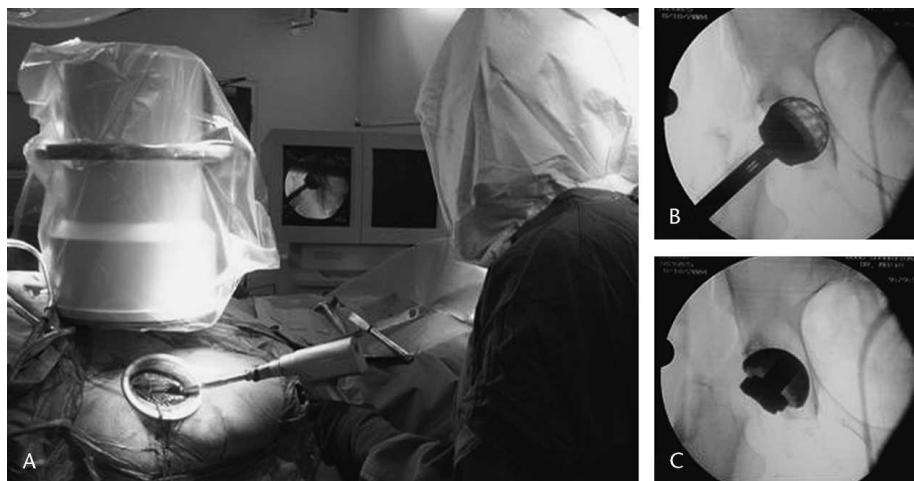


Fig 6A–C. The image intensifier can be used to verify reaming position with respect to the pelvis for immediate feedback during the procedure. The acetabular component may be placed under intensification to verify accurate abduction and anteversion.

plished with further release of the capsule and infrequently with sequential release of the obturator internus and piriformis tendons. It should not be accomplished with further elevation of the hook past a point of excessive tension on the leg, as this can lead to fracture of the greater trochanter. The obturator internus tendon inserts inside the internal lip of the greater trochanter and in difficult cases may be released to allow additional mobilization of the femur. Likewise, release of the piriformis may be done in extreme cases. The release of these rotators is preferred over the release of the obturator externus, which exerts a more medial pull and is considered by the authors to be most important in hip stability.

Broaching was accomplished with the tip of the broach entering the neck near the posterior medial cortex (Fig 8). Care must be taken to ensure the broach is not in excessive anteversion. It is possible to perforate the posterior or lateral femoral cortex because of the interference of the patient's soft tissues on the broach handle. Broaching was continued to the size indicated by the preoperative templating, and by feel and insertion depth. Proximal femoral fracture can occur with aggressive broaching.

Although we find that cerclage wires can be passed around the proximal femur without extending the 10-cm incision, the approach can be extended distally and laterally, elevating the vastus to expose more of the femur as needed. The head-neck length was indicated by the preoperative templating, and by its observed relationship to the tip of the greater trochanter. Trial reduction was done once broaching was complete; the femur hook jack was lowered, the hook was removed, the hip was flexed to neutral, and traction was applied. The hip was reduced with internal rotation and the traction was released.

The leg length and offset determination then was done with the use of an image intensifier. An image of the contralateral hip was obtained and printed, then placed on the right screen. The operated hip was imaged, and the rotation, abduction, and flexion were adjusted so the position is equivalent with the contralateral side. The image then was printed, and the two images were compared by overlying the transparencies. The bony landmarks of the femurs were aligned, and the pelvic landmarks compared (Fig 9). With the trial components inserted, the hip stability was checked in extension and external rotation by ap-

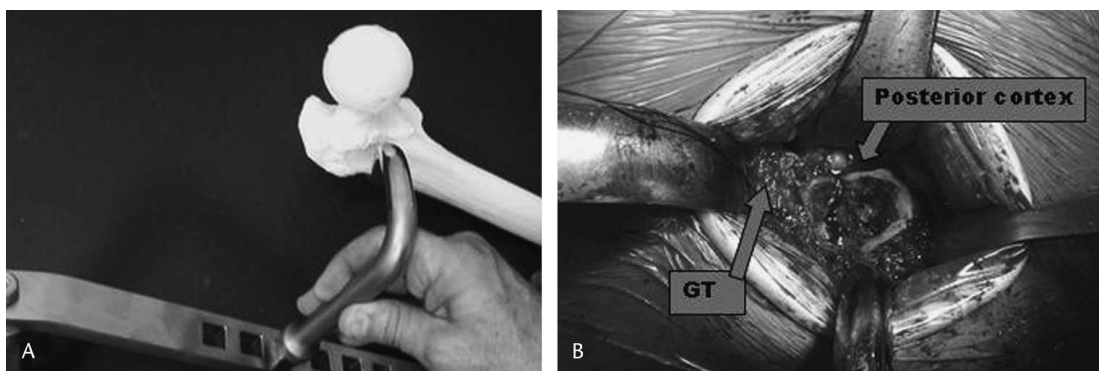


Fig 7A–B. (A) The femoral hook is placed around the vastus lateralis, just distal to the vastus ridge and around the posterior proximal femur. The femur is externally rotated and hyperextended, and the hook is placed into the bracket attachment of the table. (B) The proximal femur is exposed with a retractor placed over the greater trochanter (GT), a cobra placed behind the posterior cortex, and the hook laterally placed behind the proximal femur.




Fig 8. A photograph shows femoral broaching. The femur is well exposed for the broaching procedure. The broach enters the neck near the posterior medial cortex. Use of an offset or curved broach handle facilitates placement through the anterior wound.

plying rotation to the leg spar. Once the trial components are chosen, the hook was replaced around the posterior femur, traction applied, and the hip dislocated with external rotation and replaced into the preparation position (90° external rotation, hyperextension, adduction, and hook elevation.) The trial components were removed, the femoral prosthesis inserted, and the hip reduced (Fig 10).

The wound was checked for bleeding and the anterior and lateral capsular tag sutures tied together. Additional capsular closure can be done if desired. The fascia lata was closed with a running suture followed by subcutaneous and skin closure.

Patients were allowed weightbearing as tolerated immediately after surgery and there were no postoperative restrictions to movement or position. Walking with the aid of a crutch, cane, or walker was based on patient ability, and physical therapists in-

structed gait training and stair ambulation during the patients' hospital stay.

Of the 494 hips, 458 postoperative radiographs were available for evaluation. A low anteroposterior (AP) pelvis xray for hips and a lateral hip radiograph were routinely obtained on postoperative day 1, at 6 weeks, at 1 year, and subsequently every 2 years. The 6-week low AP pelvic radiograph was used to evaluate the acetabular component position and leg lengths. Evaluation was done by two independent orthopaedic surgeons and not the senior author (operating surgeon). This evaluation was not done in a blinded fashion.

Determination of leg length was done by measuring the vertical height from the teardrop line (a horizontal line drawn along the lower edge of the right and left acetabular tear drops, assuming pelvic symmetry) to a point chosen on the lesser trochanter considered a reproducible landmark on both sides. The vertical height to the same landmark was measured on the contralateral hip, and the difference considered the postoperative leg-length discrepancy.²⁸ When the discrepancy was greater than 1 cm, the preoperative radiographs were analyzed to determine if there was a preoperative leg-length discrepancy. The cup abduction was measured as an angle between the teardrop line and the major diameter of the ellipse represented by the rim of the acetabular cup. The sin of the anteversion angle was calculated as the length of the transverse width of the center of the acetabular ellipse divided by the length of the major diameter.

The surgical duration, estimated blood loss, and incision length were recorded at the time of surgery and retrieved through the patient database. The hospital stay was obtained from review of the patients' hospital charts. Dislocations requiring medical assistance were recorded in the database as they occurred. Operative complications were recorded as they occurred.

RESULTS

The technique allowed accurate and reproducible acetabular component insertion. Of the 494 THAs done in the

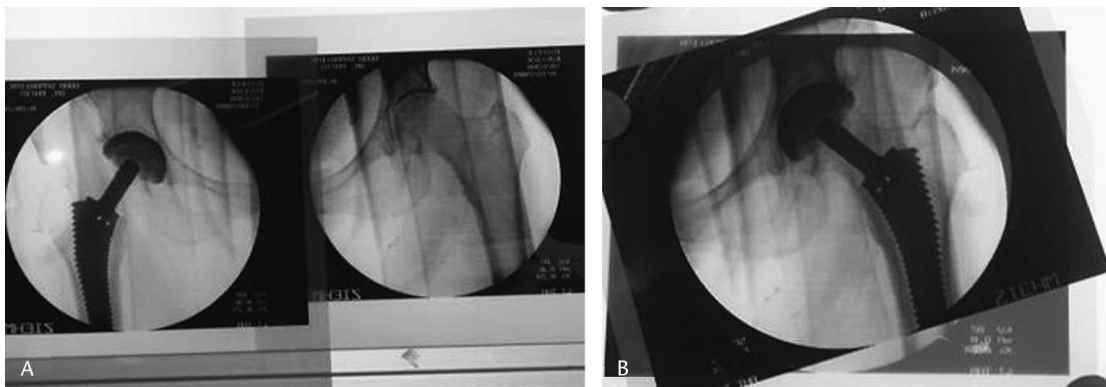


Fig 9A–B. The image intensifier is used to obtain an image of the unaffected hip. An image is taken of the trial components in the reduced position, and the two images are superimposed. The radiographic landmarks of the pelvis are lined up and the landmarks of the femur are compared to verify correct length and offset.




Fig 10A–B. The final components are placed and the hip reduced with hip flexion, traction, and internal rotation of the mobile leg spar. The component alignment is easily observed, and stability can be checked with external rotation of the leg spar.

series, 458 radiographs were available for evaluation. The mean abduction angle was $42^\circ \pm 4^\circ$ (median, 42° ; range, 34° – 54°). Ninety-six percent were placed in the target range of 35° to 50° . The average anteversion was $19.4^\circ \pm 5.2^\circ$, with a range of 0° to 30° , and 93% were within the target range of 10° to 25° .^{18,21,24}

Leg-length restoration was accurate, with an average postoperative leg-length discrepancy of 3 ± 2 mm (range, 0–26mm). Two hundred eighty-seven hips were restored to 0 to 2 mm compared with the contralateral hip, 98 showed a 3-mm to 5-mm discrepancy, 51 showed a 6-mm to 8-mm discrepancy, and 12 showed a 9-mm to 11-mm discrepancy. The preoperative radiographs of the four of the patients with a postoperative leg-length discrepancy of greater than 11 mm were evaluated, and all four had leg-length discrepancies greater than 15 mm preoperatively because of severe dysplasia. These patients had their leg lengths reapproximated to the preoperative lengths, and evaluation of their postoperative radiographs showed leg lengths within 5 mm of the preoperative length in all four instances.

Three patients (three of 494 hips) had dislocations, for a dislocation rate of 0.61%. Two of these patients had anterior dislocations and one patient had a posterior dislocation. Two of these patients had 12-cm incisions and the posterior dislocation occurred in a patient with a 10-cm incision. All of these patients had successful closed reduction under general anesthesia. All of the dislocations were limited to one episode, and none of the patients developed recurrent dislocation or required a second surgical procedure for instability.

There were 17 surgical complications, including one deep infection and three wound hematomas requiring debridement, seven proximal femoral fractures, two femoral shaft fractures, three ankle fractures, and one transient

femoral nerve palsy. Lateral femoral cutaneous nerve dysfunction was observed in the some patients during the early part of the series and the incision was moved laterally to avoid this problem. Although some patients report numbness around the incision immediately postoperatively, no patients have returned with complaints or symptoms related to lateral femoral cutaneous nerve dysfunction.

There were four fractures involving the proximal calcar region and three fracture of the greater trochanter. The calcar fractures occurred during the broaching period; in two cases the fractures were treated with weightbearing restrictions only, and both patients went on to heal without further complications. The other two were treated with cerclage wiring, accomplished without extending the incision, and both went on to uneventful recovery. Fracture of the greater trochanter can occur during the broaching period or during elevation of the femur with the hook. The surgeon must continually feel the tension applied to the leg during hook elevation because excessive tension can cause fracture. In patients in whom mobilization is required for broaching but there already is substantial tension through the hook that we do sequential releases of the obturator internus and piriformis tendons. Two fractures occurred at the distal stem, and both were treated with cerclage wires. The approach was extended distally and laterally, elevating the vastus to expose the femoral shaft.

Three patients sustained nondisplaced ankle fractures during the surgical procedure. This was an unexpected complication presumably secondary to the external rotation force used for the hip dislocation during the procedure. The surgeon now has taken additional measures to decrease the torque on the ankle and tibia during the dislocation. No ankle fractures have occurred since these precautions were instituted.

The surgical data for the 494 THAs showed an average surgical time for the procedure of 75 minutes (range, 40–150 minutes), and the average estimated blood loss was 350 mL. The average surgical time for bilateral hip arthroplasty was 2.5 hours (range, 1.8–4.2 hours). The median hospital length of stay was 3 days for patients having unilateral primary THA. For patients having bilateral THA, the median hospital length of stay was 5 days.

DISCUSSION

Since September of 1996 the senior author has used a single incision anterior approach to the hip for arthroplasty in an effort to decrease the complications and functional limitations attributed to the violation of the posterior stabilizing structures required of the posterior approach and the abductor mechanism as in the lateral approaches. We analyzed a consecutive series of 494 primary THAs done through an anterior approach from September 1996 to September 2004 to determine whether using this approach allowed accurate position of components and restoration of leg length, and if the dislocation rate after anterior exposure to the hip was higher than the rates historically reported for other approaches. The weakness of this study includes its retrospective nature and the lack of controls treated with traditional approaches. The strengths of the study include a continuous series of patients treated without selection and the systematic evaluation of the radiographs for component position and leg length.

The Heuter anterior approach to the hip has been used by Judet and Judet for hip exposure to implant an artificial femoral head for arthroplasty since in 1947.^{15,16} The surgery was facilitated by operating on the Judet table with the patient in supine position. The technique was conceived in order to use the anatomic Smith–Petersen interval between the zones of innervation of the superior and inferior gluteal nerves laterally and the femoral nerve medially. Judet reasoned that the hip is an anterior joint, closer to the skin anterior than posterior, and that the anatomic interval allowed exposure of the hip without detachment of the posterior structures, theoretically allowing immediate stability.

Since its inception, Professor Thierry Judet, Chief of Orthopedics at Garches, and his colleagues have used this approach and table for longer than 20 years and for more than 2000 patients.^{25,26} It has been the preferred technique for primary and revision hip arthroplasty at Garches since 1947. It has been used for a variety of prosthesis including the Judet acrylic, the Judet uncemented, conventional cemented, partial femoral head resurfacing, and total hip surface arthroplasty. The original incision was longer and included detachment of part of the tensor origin from the pelvis and sectioning of the reflected tendon of the rectus

femoris, but since has been modified to a mini incision without detachment or sectioning of any muscle.^{2,17,25}

Although this history of the anterior approach for THA has been little known in the orthopaedic community, the trans-trochanteric, posterior, and lateral approaches have been widely studied.^{5–7,10–14,19,22,27} Charnley implanted the first consistently successful THA in the 1960s. He positioned the patient supine and used a standard flat-topped operating table with the patient's leg draped free and manipulated by an assistant. The approach required osteotomy of the greater trochanter to separate the gluteus medius and minimus insertions from the proximal femur and subsequent reattachment after component implantation. Complications including abductor dysfunction and dislocation have been attributed to osteotomy nonunion and have led surgeons to develop exposures that avoid a trans-trochanteric approach.^{7,9,10,13}

The posterior approach remains a popular exposure for THA. The benefits of the posterior approach include surgeon familiarity, good exposure of the femur, and preservation of the gluteus medius and minimus. However, a high incidence of posterior dislocation has been reported with this exposure by many authors. The increased incidence of dislocation has been attributed to the division of the posterior hip capsule and external rotators and acetabular component malposition.^{8,11,19,27,30} Yuan and Shih³⁰ reported a dislocation rate of 3.29% after analysis of 2161 patients operated from a posterior approach. Fackler and Poss¹¹ reported a dislocation rate of 1.8% in 1224 operated with repair of the posterior external rotators. Masonis and Bourne¹⁹ evaluated the correlation of surgical approach and primary THA dislocation in a comprehensive literature review and reported that with the current data available the rate of dislocation after primary THA is 3.23% without posterior repair of the external rotators compared with 2.03% when a posterior repair was done.

The lateral approaches involve the necessary detachment of at least a portion of the gluteus minimus and medius from the greater trochanter. This approach has the advantage of a decreased dislocation rate, ranging from 0% to 2% and reported in a literature review to average 0.55%.^{12,19,22} However, the incidence of postoperative limp is reported in 4% to 20.4% of patients and has been attributed to disruption of the abductor tendon or injury to the superior gluteal nerve.^{1,12,14,22,27}

We think the main advantage of the anterior approach is that it generally is accomplished without detachment of any muscle from the pelvis or femur. The posterior structures, released in the posterior approaches and implicated in instability, are left intact and theoretically confer immediate stability to the hip, obviating the need for dislocation precautions. Furthermore, this is accomplished without violating the abductor tendon as occurs in the

lateral and anterolateral approaches. Infrequently, release of the obturator internus and piriformis is done to gain additional femoral exposure, but the obturator externus is preferentially spared in all cases. In our series there was a dislocation rate of 0.6%. A closed reduction was possible for all three patients, all were single time dislocations, and no patients have required a revision surgery for recurrent dislocation. This is similar to the dislocation rate of 0.96% reported by Siguier et al²⁵ after analysis of 1037 primary THA operated through a mini-incision anterior approach utilizing a similar surgical technique.

Acetabular orientation has been implicated in dislocation; however, optimal abduction and anteversion angles are difficult to define.^{18,21,24} Regardless of the "optimal" component orientation, an approach for arthroplasty should allow the surgeon to place the components consistently in a desired target range. Woolson et al²⁹ defined "outliers" as components positioned in $\leq 30^\circ$ or $\leq 50^\circ$ and reported a higher number of outliers in THA after a mini incision than after a standard posterior approach, questioning the safety of minimally invasive techniques.²⁹ This was not our experience. The anterior approach technique allowed accurate acetabular component positioning and leg length restoration. 96% of component abduction angles were within our desired range of 35° to 50° , and 93% of cup anteversion angles were within our target range of 10° to 25° . In our series, 78% of patients had a leg length discrepancy of 5 mm or fewer with an average discrepancy of 3 ± 2 mm. We attribute this accuracy to intraoperative image intensification, which provides immediate information regarding acetabular position, femoral length, and offset.

We consider the role of the gluteus maximus and tensor fascia lata muscles as abductors and pelvic stabilizers. These two muscles insert on the fascia lata/iliotibial band that joins them and together form a deltoid of the hip. We think that another benefit of the anterior approach is that the hip deltoid is undisturbed. Preserving the hip deltoid and the abductor tendons may avoid the risk of limp attributed to disruption of these structures. Multi-surgeon functional outcome studies have been initiated to study our perception that this approach allows a rapid return to function and decreases the rate of abductor dysfunction.

As described by Judet, we do the procedure on an orthopaedic table that allows rotational control of the femur during the procedure and facilitates femoral exposure. Kennon et al¹⁷ report on using the Heuter approach for more than 3000 THAs done using a standard flat table. They reports that secondary incisions for acetabular and/or femoral preparation are often required, and this technique also involves splitting the medial portion of the tensor fascia lata muscle. In contrast, we have not required a

second incision for component placement. We think that the use of the orthopaedic table improves femoral access, decreases the necessity of secondary incisions and reduces muscle trauma that can result from forceful retraction.

We think this technique has several advantages compared with other described minimally invasive approach for THA. Unlike many mini-incision techniques, the procedure can be done on any patient, and there is no need to select qualified patients based on body habitus.^{3,29} The only patients treated with an approach other than the anterior approach at this time are patients with previous acetabular fractures associated with posterior heterotopic ossification (not yet excised), and/or pelvic deformity associated with substantial posterior acetabular defects. The anterior approach also is advantageous for the patient with bilateral hip disease.²⁰ The supine positioning allows a short anesthetic time because there is no need to reposition and redrape during the surgery. The total surgical time for patients having bilateral arthroplasties averaged 2.5 hours.

This tissue-sparing anterior approach to THA allows consistent component positioning and leg length restoration. We think that the dislocation rate of 0.61% is relatively low when compared with the current literature, and is certainly not higher than the reported rates of dislocation. The technique has the advantage of being applicable to all patients without a posterior acetabular defect. The abductor tendon and the hip deltoid are not disturbed and a multicenter study has been initiated to test our perception that patients benefit from a rapid functional return and reduced risk of abductor dysfunction.

Acknowledgment

We would like to thank Niki Delacueva for her assistance with data collection and database management.

References

1. Baker AS, Bitounis VC: Abductor function after total hip replacement: An electromyographic and clinical review. *J Bone Joint Surg* 71B:47-50, 1985.
2. Beaulé PE, Griffin DB, Matta JM: The Levine anterior approach for total hip replacement as the treatment for an acute acetabular fracture. *J Orthop Trauma* 18:623-629, 2004.
3. Berger RA: Total hip arthroplasty using the minimally invasive two-incision approach. *Clin Orthop Relat Res* 417:232-241, 2003.
4. Bourne RB, Rorabeck CH: Soft tissue balancing: The hip. *J Arthroplasty* 17:17-22, 2002.
5. Charnley J: Total prosthetic replacement of the hip. *Reconstr Surg Traumatol* 11:9-19, 1969.
6. Charnley J: The long-term results of low-friction arthroplasty of the hip performed as a primary intervention. *J Bone Joint Surg* 54B:61-76, 1972.
7. Coventry MB: Late dislocations in patients with Charnley total hip arthroplasty. *J Bone Joint Surg* 67A:832-841, 1985.
8. DeWal H, Su E, DiCesare PE: Instability following total hip arthroplasty. *Am J Orthop* 32:377-382, 2003.

9. Eftekhar N: Dislocation and instability complicating low friction arthroplasty of the hip joint. *Clin Orthop Relat Res* 121:120–125, 1976.
10. Etienne A, Cupic Z, Charnley J: Postoperative dislocation after Charnley low-friction arthroplasty. *Clin Orthop Relat Res* 132:19–23, 1978.
11. Fackler CD, Poss R: Dislocation in total hip arthroplasties. *Clin Orthop Relat Res* 151:169–178, 1980. Frndak PA, Mallory TH, Lombardi Jr AV: Translateral surgical approach to the hip: The abductor muscle “split”. *Clin Orthop Relat Res* 295:135–141, 1993.
12. Frndak PA, Mallory TH, Lombardi Jr AV: Translateral surgical approach to the hip: The abductor muscle “split”. *Clin Orthop Relat Res* 295:135–141, 1993.
13. Hardinge K: The direct lateral approach to the hip. *J Bone Joint Surg* 64B:17–19, 1982.
14. Horwitz BR, Rockowitz NL, Goll SR, et al: A prospective randomized comparison of two surgical approaches to total hip arthroplasty. *Clin Orthop Relat Res* 291:154–163, 1993.
15. Judet J, Judet R: The use of an artificial femoral head for arthroplasty of the hip joint. *J Bone Joint Surg* 32B:166–173, 1950.
16. Judet R, Judet J: Technique and results with the acrylic femoral head prosthesis. *J Bone Joint Surg* 34B:173–180, 1952.
17. Kennon RE, Keggi JM, Wetmore RS, et al: Total hip arthroplasty through a minimally invasive anterior surgical approach. *J Bone Joint Surg* 85A:39–48, 2003.
18. Lewinnek GE, Lewis JL, Tarr R, et al: Dislocation after total hip arthroplasties. *J Bone Joint Surg* 60A:217–220, 1978.
19. Masonis JL, Bourne RB: Surgical approach, abductor function, and total hip arthroplasty dislocation. *Clin Orthop Relat Res* 405:46–53, 2002.
20. Matta JM: Bilateral THA. *Orthopedics* 25:1224, 2002.
21. McCollum DE, Gray WJ: Dislocation after total hip arthroplasty: Causes and prevention. *Clin Orthop Relat Res* 261:159–170, 1990.
22. Moskal JT, Mann III JW: A modified direct lateral approach for primary and revision total hip arthroplasty: A prospective analysis of 453 cases. *J Arthroplasty* 11:255–266, 1996.
23. Padgett DE, Warashina H: The unstable total hip replacement. *Clin Orthop Relat Res* 420:72–79, 2004.
24. Robbins GM, Masri BA, Garbuz DS, Greidanus N, Duncan CP: Treatment of hip instability. *Orthop Clin North Am* 32:593–610, 2001.
25. Siguier T, Siguier M, Bertrand B: Mini-incision anterior approach does not increase dislocation rate. *Clin Orthop Relat Res* 426:162–173, 2004.
26. Siguier T, Siguier M, Judet T, Charnley G, Brumpt B: Partial resurfacing arthroplasty of the femoral head in avascular necrosis: Methods, indications, and results. *Clin Orthop Relat Res* 386:85–92, 2001.
27. Vicar AJ, Coleman CR: A comparison of the anterolateral, trans-trochanteric, and posterior surgical approaches in primary total hip arthroplasty. *Clin Orthop Relat Res* 188:152–159, 1984.
28. Woolson ST, Hartford J, Sawyer A: Results of a method of leg-length equalization for patients undergoing primary total hip replacement. *J Arthroplasty* 14:159–164, 1999.
29. Woolson ST, Mow CS, Syquia JF, Lannin JV, Schurman DJ: Comparison of primary total hip replacements performed with a standard incision or a mini-incision. *J Bone Joint Surg* 86A:1353–1358, 2004.
30. Yuan L, Shih C: Dislocation after total hip arthroplasty. *Arch Orthop Trauma Surg* 119:263–266, 1999.